Cardiovascular Update

January 2018 | Volume 3, Issue 1

A newsletter from the BayCare Cardiovascular Service Line

Cardiac Computed Tomography

By Michael O. Barry, MD

Michael O. Barry, MD

Noninvasive Cardiology,
Morton Plant Mease and
Structural Heart and Valve Clinic

Overview

Recent rapid technologic advances have contributed to the widespread clinical use of cardiac computed tomography (CT). Using CT scanners with 64 or more detectors have demonstrated great accuracy for detecting significant coronary artery disease (CAD). The CT scanners have high enough spatial resolution to resolve fine structures and sufficient temporal resolution to freeze coronary motion. Cardiac CT imaging began predominately with the advent of the 64-detector scanners; however, technology has progressed to 320-detector scanners and dual-source scanners, both of which have increased the spatial and temporal resolution. Additionally, the technology has reduced the patient radiation exposure to 8-5 mSv and, with most recent advancements, potentially less than 1 mSv. Cardiac CT imaging can either be a calcium score and/or a coronary computed tomography angiography (CCTA).

Patient Preparation

Patients are usually medicated with a beta blocker or calcium channel blocker medication to achieve a heart rate in the 60s and minimize heart rate variability to improve image quality. If the patient has renal insufficiency, hydration is recommended either with intravenous or oral fluids. Morbid obesity reduces image quality and should be considered when selecting imaging type. Depending on the advancements of the scanner, atrial fibrillation or other irregular heart rhythms may preclude coronary evaluation. Atrial fibrillation or other irregular heart rhythms will not preclude cardiac morphologic evaluation. Other contraindications include advance renal insufficiency, profound contrast allergy or extensive coronary artery calcium.

Image Review

The CT images are typically viewed in the diastolic phases (least amount of cardiac motion), obtained by either a retrospective EKG-gated helical scan or prospective EKG-gated scan. A variety of post-processing techniques are useful in CCTA. The images can be reviewed in an axial format, curved multiplanar reformat (CPR), maximum intensity projections (MIP) or volume rendered technique (VRT) *(figure 1)*.

Fig. 1

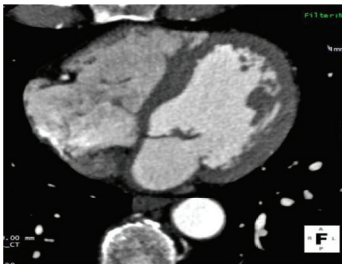

Axial format

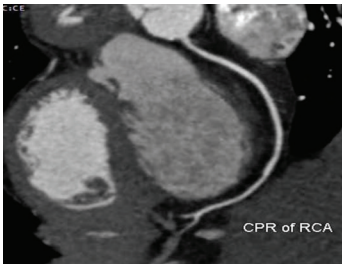

Curved multiplanar reformat

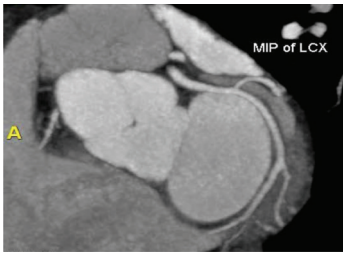

Maximum intensity projections

Volume rendered technique

Continued on page 2

Clinical Applications

Calcium scoring and coronary computed tomography angiography (CCTA) have different clinical indications. Calcium scoring is used for risk stratification of asymptomatic patients, while CCTA is primarily used in patients with acute or chronic chest pain or cardiac morphology evaluation.

The ACC/AHA produced appropriateness guidelines for cardiac CT in 2010[1]. The guidelines include many appropriate level recommendations *(table 1 and 2, page 3)*. However, according to the guidelines, there are many clinical situations where the appropriateness is uncertain. Therefore, consultation with a cardiovascular specialist would be fitting to help decide which cardiac test would be the highest yield: CCTA, stress testing or cardiac catheterization.

Calcium Scoring

Calcium scoring is primarily used for risk stratification of asymptomatic patients and is completed with a non-contrast-enhanced CT. Calcium scoring is completed with a semi-automated tool to calculate the extent of coronary artery calcium *(figure 2)*. Typically, the calcium score or Agatston score is divided into three categories based on severity of calcification and subsequent CAD. The categories include low risk (score 0–100), intermediate risk (score 100–400) and high (score >400). The higher the calcium score translates into higher cardiovascular mortality risk[2].

The calcium score can be done independently for risk stratification or done prior to CCTA. If non-contrast CT shows a calcium score great than 400, often the CCTA is avoided due to the reduced accuracy in the setting of a high calcium score. High calcium score findings in asymptomatic patients warrant aggressive risk factor modification with high-intensity statin therapy, aspirin treatment, blood pressure control and regular exercise.

Fig. 2

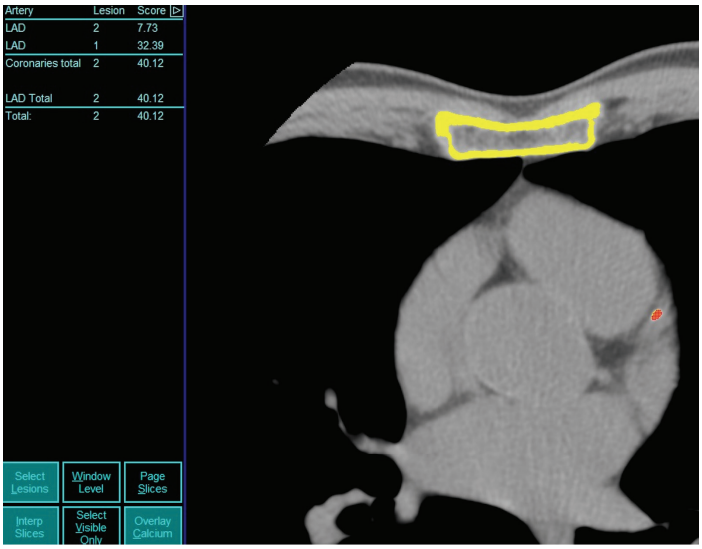

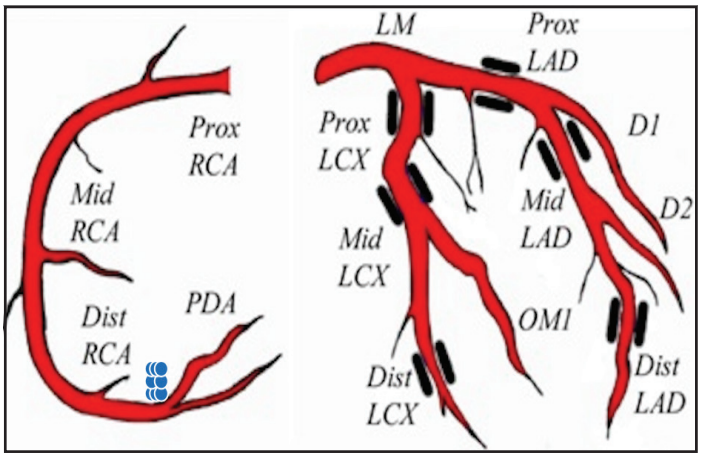

The diagram above is a schematic of the coronary artery system. The coronary arteries are segmented into Proximal, Mid, and Distal sections, which may be annoted with black markings to illustrate the **approximate location** of any **calcified** regions detected in examination. However, please note that the marlkings **do not imply** the presence, absence, location or extent of arterial stenosis or any other condition other than the presence of coronary calcification.

Agatston Score

Coronary Artery	Score
Left Main (LM)	0.00
Left Anterior Descending (LAD)	511.27
Left Circumflex (LCX)	38.46
Right Coronary Artery (RCA)	0.00
Total Agatston Score	**549.73**

The **Agatston Score** as reported in this table provides a measure for comparison with published studies (see Percentile Ranking to the right). The **Volume Score** can be useful for comparison with follow-up examinations, and is reported here: **394.31 mm**.

Percentile Ranking

<75%

In a published study, greater than 75% of people of the same gender and similar age had the same or lower scores.

The Percentile Ranking compares this score with scores for people in a group with the same gender and similar age, as reported in the literature. A rank **below** 50% indicates a score **better** than most in that group. A rank **above** 50% indicates a score **worse** than most in that group. *(J Hoff et al.,* American Journal of Cardiology, *2001 87:1335-1339)*.

Coronary Computed Tomography Angiography (CCTA)

CCTA allows for high resolution evaluation of the heart in a safe and rapid manner. CCTA is accurate for detecting CAD of greater than 50 percent stenosis. In a meta-analysis comparing CCTA to conventional coronary angiography as the reference standard, CCTA had a sensitivity of 96 percent and a specificity of 86 percent[3]. CCTA does allow for coronary stent evaluation; however, the evaluation is limited by the small size of the coronary stent and metallic attenuation artifact. CCTA for stent assessment is typically defined as patent or close, and percentage restenosis is not rendered due to inaccuracy.

There are many indications for CCTA beyond evaluating for CAD. The appropriate indications for CCTA have been outlined in tables 1 and 2. The recent expansion of catheter-based structural heart treatments such as left atrial appendage occlusion devices and transcatheter aortic, pulmonic and mitral valve replacement, all require CCTA to allow highly accurate sizing measurements to be made prior to the implantation procedure.

Future Applications

A growing body of evidence supports the use of functional CT imaging called CT-derived fractional flow reserve (FFRCT). FFRCT is a computational fluid dynamics modeling technique that can be applied to a CCTA dataset for estimating lesion-specific functional information of a coronary stenosis without requiring any protocol modifications[4]. This is a proprietary model from HeartFlow (Redwood City, CA). Thus, no additional radiation is required to acquire this data. FFRCT is complementary to CCTA and offers greater specificity and positive predictive value for detecting hemodynamically significant CAD, compared with anatomic imaging alone. This technique combines anatomic imaging with perfusion or functional information.

Conclusions

Cardiac CT is a rapidly evolving imaging modality not only due to scanner technology improvements but also due to new clinical applications of the imaging data. Consultation with a cardiovascular specialist will help guide the appropriate cardiac imaging selection.

Table 1

Appropriate Indication for CCTA: CAD Evaluation

- Symptoms with intermediate CAD risk with interpretable EKG and able to exercise
- Symptoms with low or intermediate CAD risk with uninterpretable EKG or unable to exercise
- Symptoms with low or intermediate CAD risk with normal or uninterpretable EKG with equivocal cardiac biomarkers
- New onset or newly diagnosed clinical CHF with reduced EF with low or intermediate CAD risk
- Coronary artery evaluation before non-cardiac surgery with intermediate CAD risk
- Prior normal EKG exercise stress test with continued symptoms
- Re-evaluation of new or worsening symptoms with previous normal stress imaging study
- Discordant EKG exercise results and imaging results on stress test
- Equivocal findings on stress imaging procedures
- Intermediate risk coronary artery calcium score of 100–400
- Evaluation of graft patency after CABG

Table 2

Appropriate Indication for CCTA: Structure and Function

- Assessment of coronary anomalies or thoracic arteriovenous vessels
- Assessment of adult congenital heart disease
- Evaluation of left ventricular function with inadequate images from other noninvasive testing
- Assess right ventricular function and suspect arrhythmogenic right ventricular dysplasia
- Characterization of native cardiac valves and annulus size prior to transcatheter based valve replacement
- Evaluation of cardiac masses (tumor or thrombus)
- Evaluation of pericardial anatomy
- Evaluation of pulmonary vein anatomy prior or post radiofrequency ablation of atrial fibrillation
- Evaluation of coronary vein anatomy prior to biventricular pacemaker placement
- Localization of coronary bypass grafts and retrosternal anatomy prior to repeat chest surgery
- Evaluation of left atrial appendage anatomy and size prior to closure procedures

References:

1. Taylor et al. ACCF/SCCT/ACR/AHA/ASE/ASNC/NASCI/SCAI/SCMR 2010 Appropriate Use Criteria for Cardiac Computed Tomography. Journal of the America College of Cardiology. Nov 2010, 56 (22) 1864-1894.
2. Budoff MJ, Nasir K, McClelland RL, et al. Coronary calcium predicts events better with absolute calcium scores than age-sex-race/ethnicity percentiles: MESA (Multi-Ethnic Study of Atherosclerosis). J Am Col Cardiol 2009;53:345-52.
3. Gorenoi et al. CT coronary angiography vs. invasive coronary angiography. GMS Health Technology Assessment 2012, Vol. 8, 1861-1863.
4. Nørgaard BL, Leipsic J, Gaur S, et al. Diagnostic performance of noninvasive fractional flow reserve derived from coronary computed tomography angiography in suspected coronary artery disease: the NXT trial (Analysis of Coronary Blood Flow Using CT Angiography: Next Steps). J Am Coll Cardiol 2014;63:1145-55.

BayCare